

60 Years Journey of Palatal Expansion: Evidence-Based, Data Informed Evolution of Airway, Palatal Expansion Protocols and Future Directions




Prof. Dr. Ahmet Keles

Pt. Faculty, Harvard School of Dental Medicine,
Orthodontics Dept, Boston, MA. USA
Private Practice, Istanbul, TURKEY



1

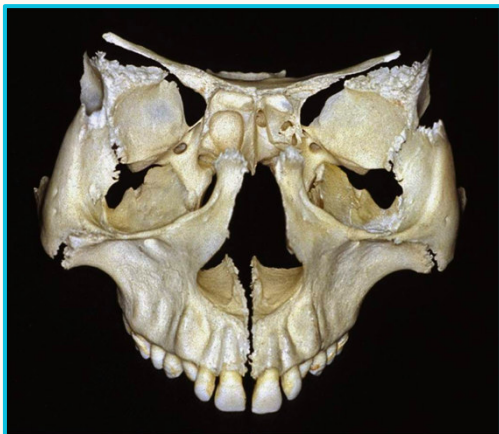

Winter in Boston



Spring in Boston

2

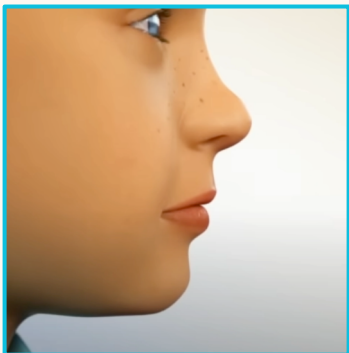


Maxillary transverse constriction is among the most common malformations in orthodontics and posterior crossbite has been reported to occur between 20-25% of the population


3

What causes maxillary constriction?


- Heredity
- Bad Habits



Thumb sucking



Tongue thrust



4

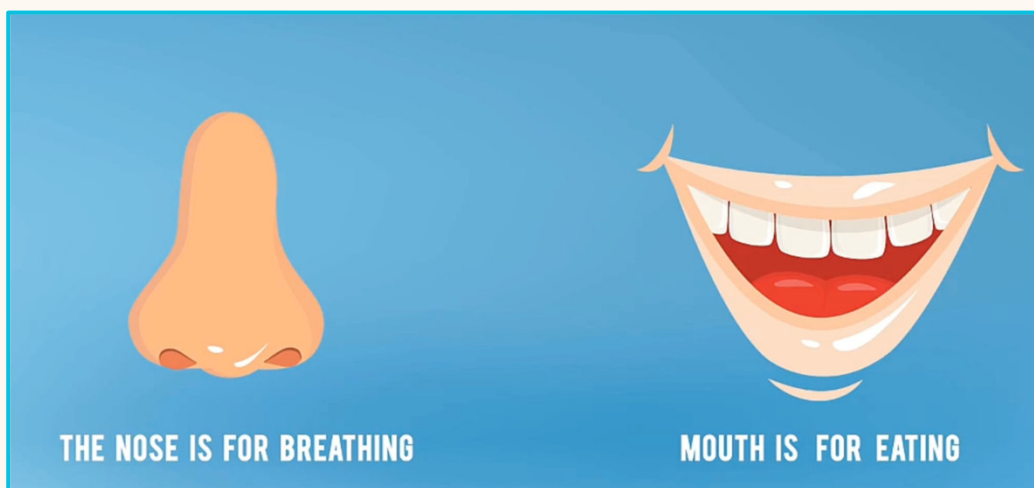
Environmental factors which causes maxillary constriction:



- Air Pollution
- Nasal inflammation
- Hypertrophied tonsils and adenoids
- Allergies
- Mouth breathing

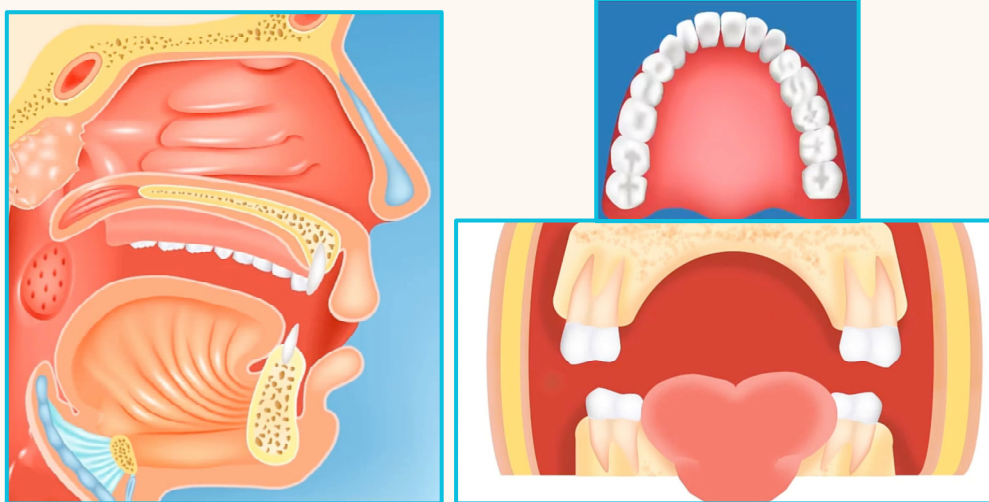


5



6

Nasal Breathing/Mouth Breathing:



7

Class II/maxillary transverse deficiency



- Most Class II patients in mixed dentition are associated with maxillary constriction.
- The first step in the treatment is expansion of the maxilla.

Maxillary adaptations to expansion in the mixed dentition.

L Spillane and J McNamara, Seminars in Orthodontics 1995:1(3); 176-187

8

Class III/maxillary transverse deficiency



- Constriction of maxilla is a condition that occurs 50% of all Class III patients.

*Maxillary adaptations to expansion in the mixed dentition.
L Spillane and J McNamara Seminars in Orthodontics 1995:1(3); 176-187*

9

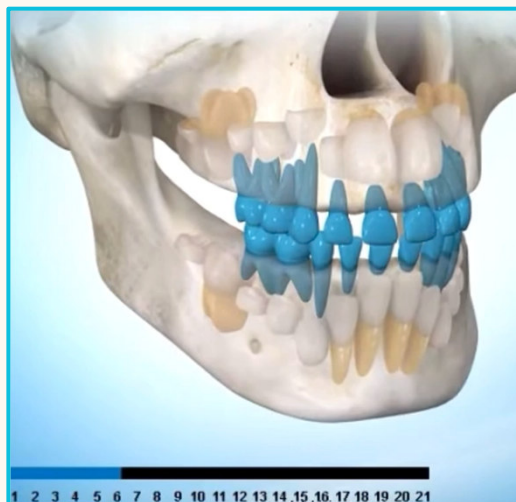
What is the effect of palatal expansion?



- Widen the palate, create space for alignment of teeth, avoid patients from extraction of permanent teeth and future extended orthodontic treatment with braces.
- Skeletally coordinate the relationship of underdeveloped maxilla with mandible for better function and esthetics.
- Improve the nasal breathing/oxygen intake and general well being of the patient.

10

Eruption sequence in mixed dentition from age 6-12 years old.



11

Why Early Intervention Matters



The Core Argument

Early, short-term interceptive orthodontic treatment during the mixed dentition phase can:

- Correct certain malocclusions
- Reduce complexity of later treatment
- Eliminate need for invasive puberty-stage procedures
- Lower overall cost burden

Staderini et al., 2022

Early short-term interceptive treatment can reduce complexity or avoid the necessity of complex and expensive procedures during puberty

Dimberg et al., AJODO 2015

Systematic interceptive treatment during mixed dentition is more effective than no treatment for reducing malocclusion complexity.


Barreto et al., 2025

The 2x4 appliance is effective interceptive therapy; 71% of patients completed treatment in a single phase, with extraction rate <1%.

Staderini et al. (2022) PMID:39181852; Dimberg et al. (2015) AJODO; Barreto et al. (2025) PMID:40723021


12

What is the earliest dental age I start palatal expansion?



- Following the eruption of the upper first molars, as well as the upper central incisors and lower incisors (typically around 7 to 8 years of age)

13



Method:

A systematic review was conducted using 12 clinical studies evaluating anatomical and functional respiratory changes after RME in children with mouth breathing or sleep apnea.

Results:

RME consistently resulted in significant increases in nasal cavity volume and upper airway dimensions. Multiple studies reported reductions in the apnea-hypopnea index, improved oxygen saturation, and better sleep quality.

Conclusions:

RME is effective in enhancing nasal breathing and reduction of apnea symptoms in children.

14

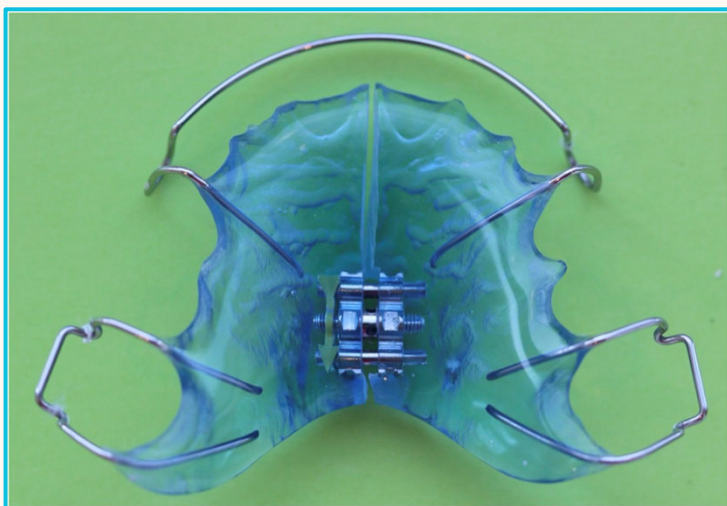
What are the treatment options?



- Either slow or rapid palatal expansion.
- Extraction in later stage when the patient is in permanent dentition.

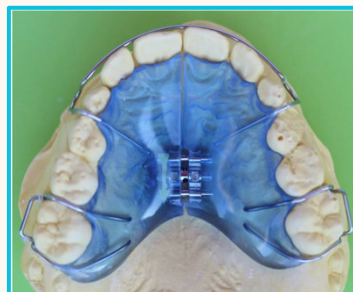15

Slow expansion in mixed dentition: *Schwarz Expander Removable Orthodontic Appliances (1966)*




Downsides

The success of the treatment solely depends on [patient cooperation](#)
Long Tx duration (1-2 years)



16


Align Technology launched a new appliance

CONTACT US 


Invisalign Palatal Expander (IPE) was launched at AAO Annual Meeting in New Orleans, May 2024


The world's most innovative palatal expander

Invisalign aligners changed the game. Now we're doing it again.



View site information






Say goodbye to daily screw-turning
Every set of expanders is custom-fit to your child's mouth and 3D-printed for a sleek design, and a more comfortable¹ and less anxiety-inducing experience¹—for your child and for you.

Clinically proven to be safe and effective.²
The era of traditional expanders is over. The Invisalign Palatal Expander System is the only FDA-cleared, removable palatal expander that's just as effective as traditional expanders.²

Removable for better oral hygiene.³
With no metal or wires in the way, your child can easily pop out the Invisalign Palatal Expander to brush and floss as usual.

17



Social Media Advertisement

Align tells the public traditional expanders are *medieval* or *barbaric*

18

AAO letter to Align Technology on August 21 2024

CONTACT US



Dr. John Callahan, President of the AAO, has contacted Align on behalf of AAO members regarding recent advertisements for the Invisalign Palatal Expander System. The ads contrast traditional metal expanders with the Invisalign system, suggesting that the former is painful and stressful.

The AAO is concerned that this portrayal harms the perception of traditional expanders and the orthodontists who use them.

19



- Invisalign suggests the patients to wear their IPEs full-time, even while eating.
- It's made from nylon plastic material

20

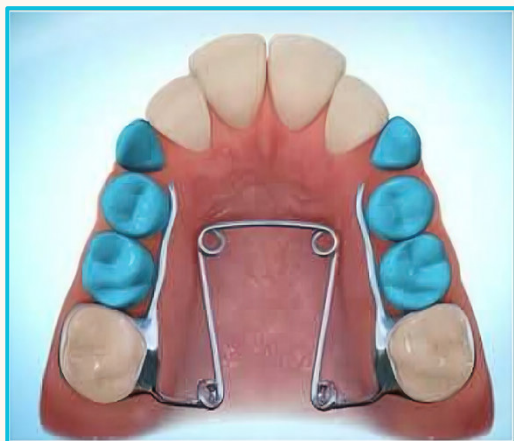Biomechanics and Compliance?



- The force tips the molar crowns buccally, Tooth-born, not true skeletal expansion → high relapse tendency
- Removable = Can be easily lost by young children; compliance issue?
- Complex tracking (multiple expanders, daily changes, 24 hr. wear)
- High cost (~\$700) for the doctor
- Environmentally wasteful (40 plastic expanders for 10 mm expansion)

21

Quad Helix Appliance: *Introduced by Robert Ricketts 1975*




Downsides

- Uncontrolled buccal tipping of molars
- Dental expansion rather than skeletal expansion

22

The
ANGLE ORTHODONTIST
An International Journal of Orthodontics and Dentofacial Orthopedics since 1930

▶ Angle Orthod. 2024 May 10;94(5):512–521. doi: [10.2319/010424-9.1](https://doi.org/10.2319/010424-9.1) 

Skeletal effects of posterior crossbite treatment with either quad helix or rapid maxillary expansion: a randomized controlled trial with 1-year follow-up

[Stina Hansson](#)^a, [Eva Josefsson](#)^b, [Henrik Lund](#)^c, [Silvia Miranda-Bazargani](#)^d, [Anders Magnuson](#)^e, [Rune Lindsten](#)^f, [Farhan Bazargani](#)^{g,✉}

23

They randomized 42 patient with a mean age of 9.5 years into two groups



They Concluded:


- The quad helix did not open the mid-palatal suture, the effect is dental rather than skeletal expansion.
- Importantly, more buccal bone loss and fenestrations were found with the Quad Helix than the RME.

24

The traditional Hyrax expander we use today was introduced by Biderman in 1968 (58 years ago)



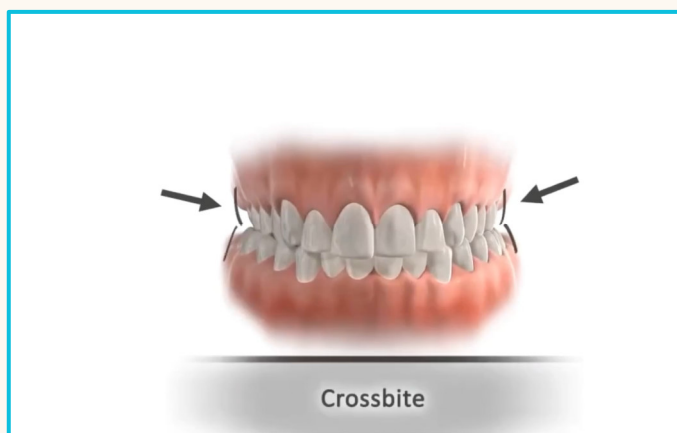
Conventional RPE screw



Key

25

How does it work?



26

Downside of the traditional RPE screws:



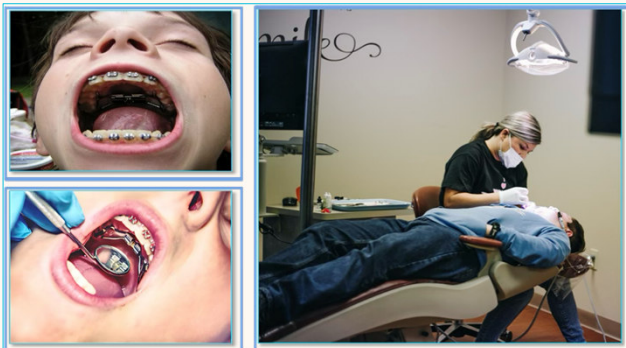- Loosing the key
- Not able to locate the hole to insert the key (food debris)
- Injuries to the palate during the insertion of the key
- If the turn of the screw was not made completely with the key, the next hole for the subsequent turn would not appear.
- Not able to activate the expander by oneself (you need a guardian)
- Large size of the RPE screw (Speech and eating discomfort)
- Delayed treatment duration due to failure of activation
- Risk of swallowing the key

27

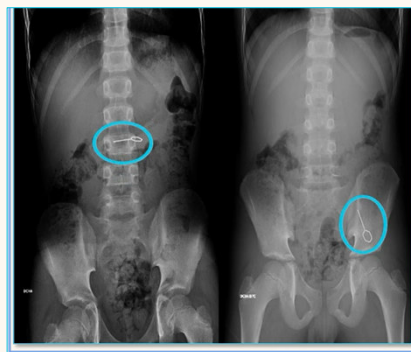
A Great Variety of Issues



Parents are expected to do this daily for 8 weeks.



Swallowed key




28

... A Product Prone to Errors



Errors in following the rapid palatal expansion activation protocol are not uncommon. These errors could consist in missed or added activations to the number prescribed by the orthodontist, more often in missed activations.

	Frequency (at patient level)
Patients with Missed Activation	63.1% (29 over 46 patients)
Patients with Extra Activation	36.9% (17 over 46 patients)



29

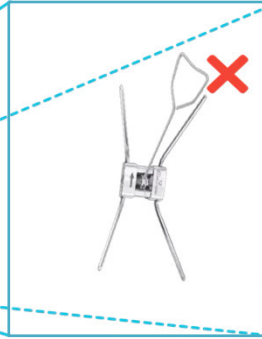
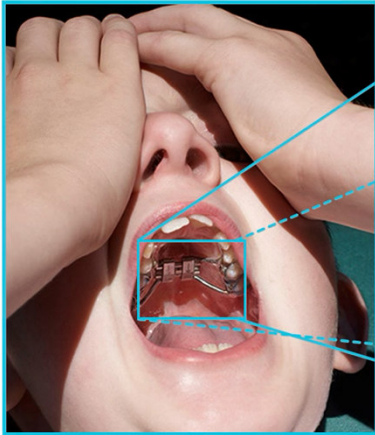
“Hey Dad, I lost the key again!”



The idea for the Keles Keyless Expander came from my son's childhood experience, as he frequently lost the activation key.

30

Why Not Make It Keyless?

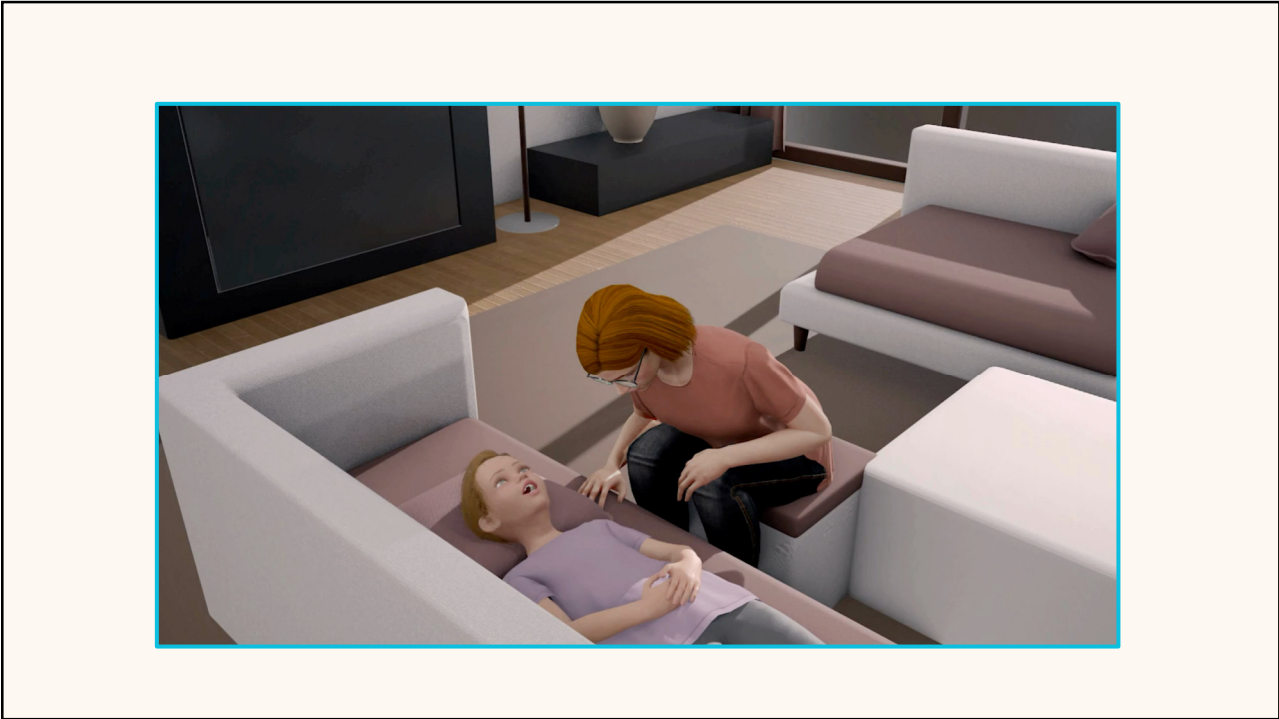


Keyless Expander

31

Our Solution:
Keyless

32



33

Keles® Keyless Expander (KKE)



CONTACT US



34

Keles® Keyless Expander (KKE)




CONTACT US



35


KKE comes with or without legs depends on doctors and labs preference

CONTACT US



36

Can be easily integrated with metal 3D printed framework.



37



KKE comes in 3 different sizes




8mm, 10mm, 12mm

38

During the development of KKE's unidirectional wheel/arm mechanism we received consultancy from a high-end watch maker for high precision and quality



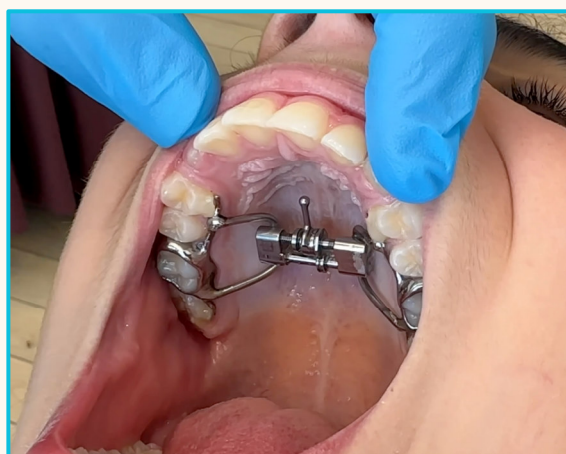
How mechanical watch works



KKE

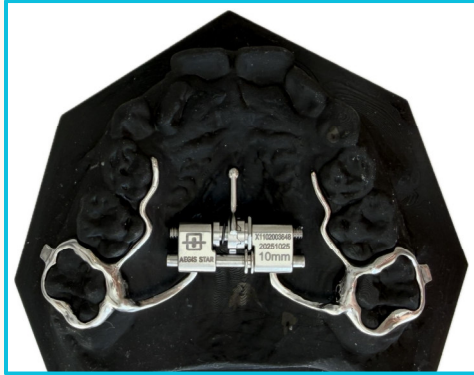39

Activation of the KKE in the mouth

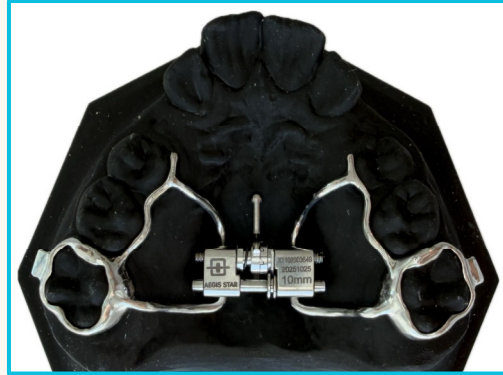

40

KKE designs:



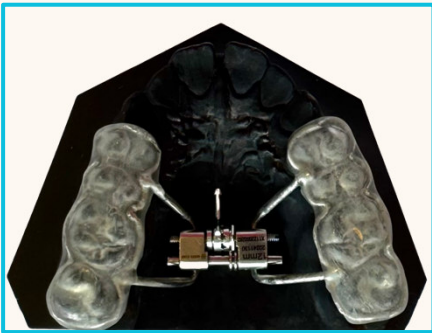
2 leg design



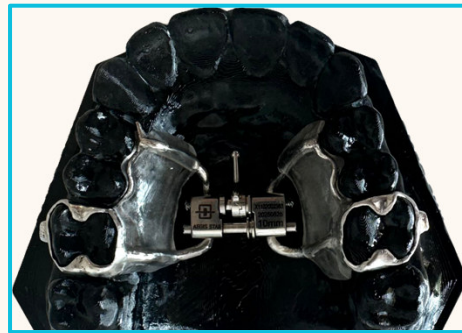
4 leg design

41

KKE designs:





Bonded design



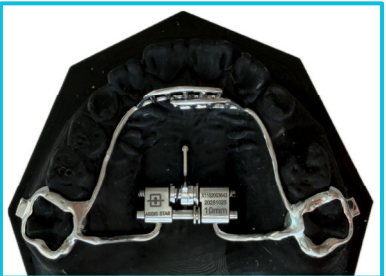
KKE/Haas

42

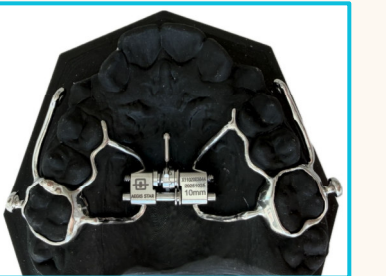
KKE designs:



Hybrid design with prongs



Hybrid design with crib



Hybrid design with FM hooks

43

KKE designs with TADs:



Hybrid design




2 TAD design (Bone-born)



4 TAD design (Bone-born)

44


>3,000 Patients Treated



CONTACT US

45

Our preliminary investigation about KKE:

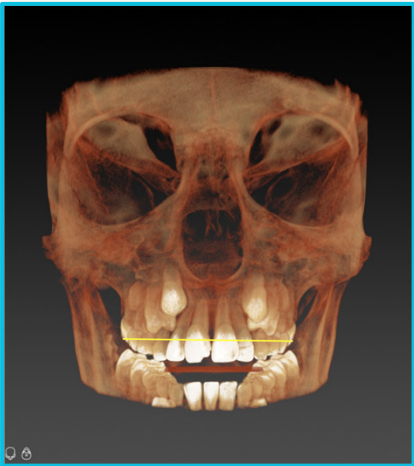



CONTACT US

We conducted a clinical trial on 34 growing children in mixed dentition with a mean age of 9.68 ± 1.54 years underwent RRE as part of their comprehensive orthodontic treatment with 3D metal printed KKE. The appliance were activated 1 turn/day. Depending on the expansion amount, the activation period ranged from 4 to 6 weeks. CBCT images were taken immediately before and 6 months after the expansion. All CBCT data were processed with KLS Martin IPS Case Designer software. After orienting the CBCT images, a set of linear and volumetric parameters were measured and calculated with Wilcoxon signed-rank and paired t-test for statistical analysis.

46

Intermolar with increase: 4,75mm

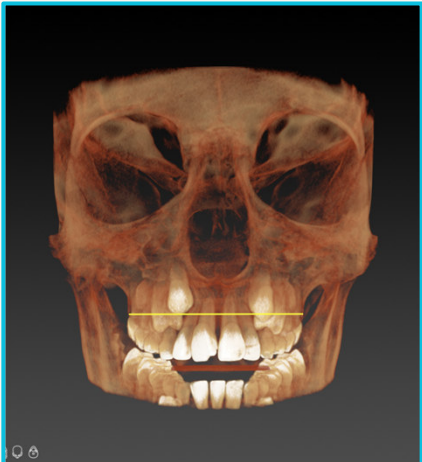



Inter-molar distance		
T0	T1	T1-T0
53,38 ± 3,90	58,13 ± 3,95	4,75 ± 1,77

p < 0,001

47


Maxillary width increase: 3,64mm



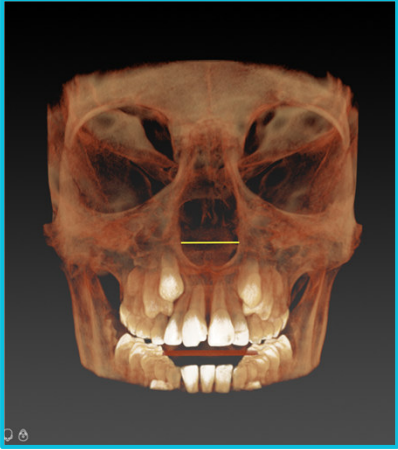
Maxillary distance		
T0	T1	T1-T0
54,95 ± 3,44	58,59 ± 4,43	3,64 ± 2,42

p < 0,001

48

CONTACT US



Nasal width increase: 1,87mm



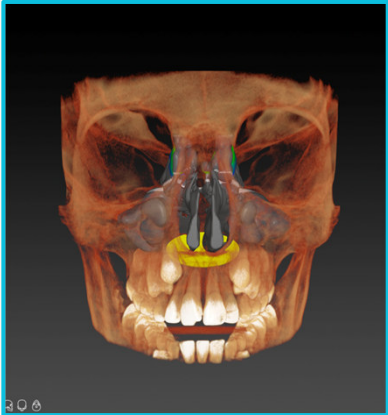
Apertura Piriformis		
T0	T1	T1-T0
22,83 ± 1,86	24,70 ± 2,28	1,87 ± 0,92


$p < 0,001$

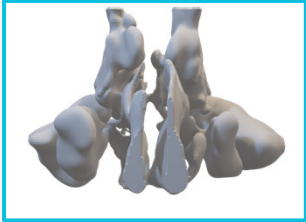
49

CONTACT US


Nasal volume increase: 6.47cm³ (23% increase)









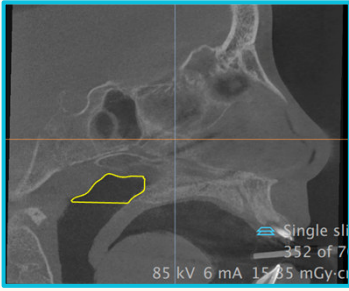

Nasal Cavity		
T0	T1	T1-T0
40,05 ± 17,91	46,52 ± 18,56	6,47 ± 3,69

$p < 0,001$

50

CONTACT US



Nasopharynx volume increase: 2,38cm³ (20% increase)


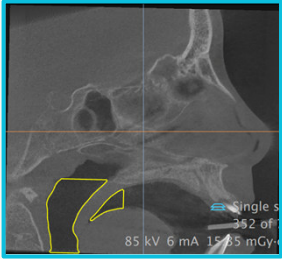

Nasopharynx		
T0	T1	T1-T0
9,43 ± 4,01	11,81 ± 4,47	2,38 ± 1,81

p < 0,001

51

CONTACT US



Oropharynx volume increase: 0,89cm³


Oropharynx		
T0	T1	T1-T0
10,55 ± 3,46	11,44 ± 3,51	0,89 ± 0,44

52

9 year old male with a round face




CONTACT US




53

Class II profile with retrognathic mandible

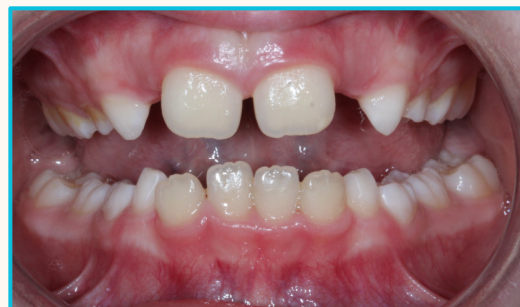
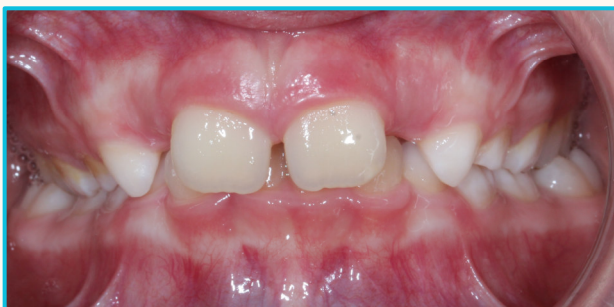

CONTACT US



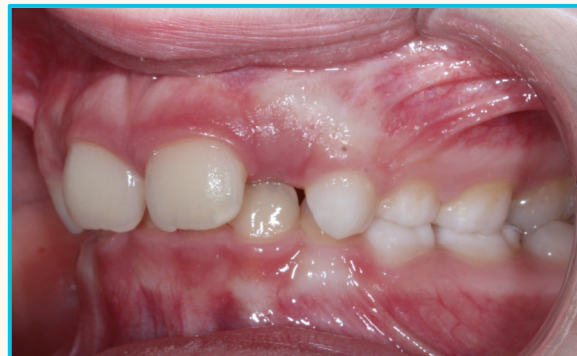
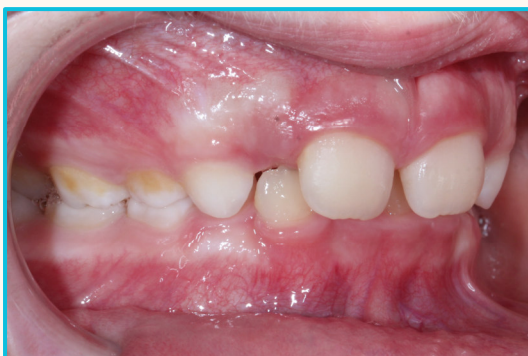54

Deep impinging bite, lack of space for the eruption of upper laterals and posterior constriction with cross bite



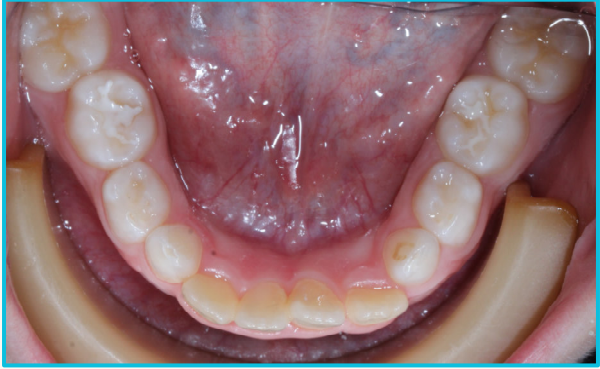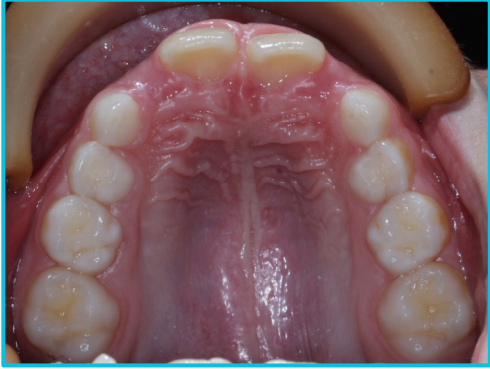55

Class II molars and deep impinging bite



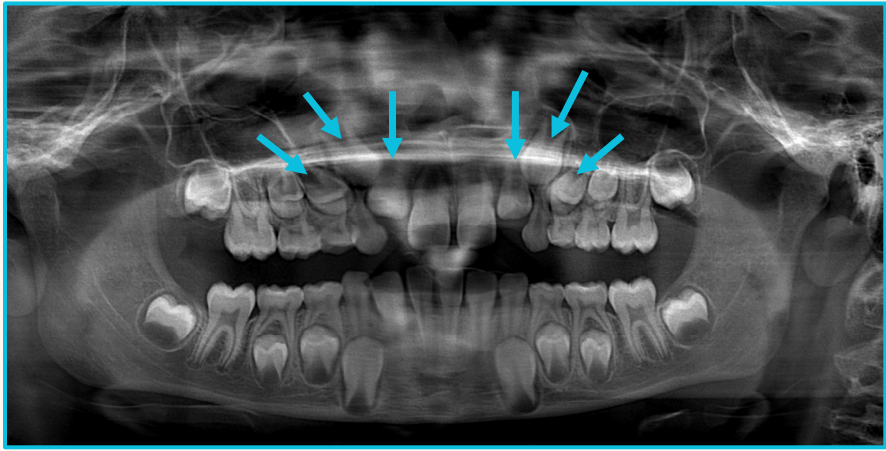
56

Constricted upper and lower posterior teeth



57

Blocked upper laterals and canines



58

Treatment plan:



Two phase orthodontic treatment :

First phase:

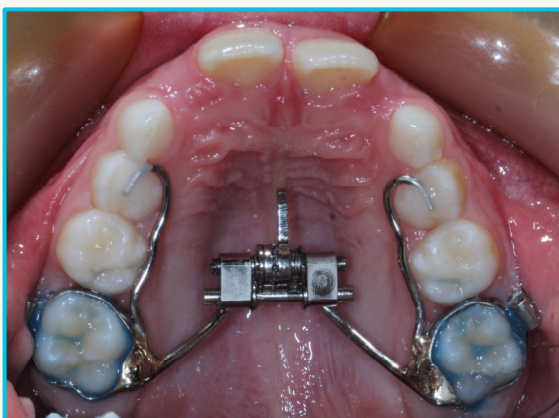- RPE with 2 arm design KKE

Second phase:

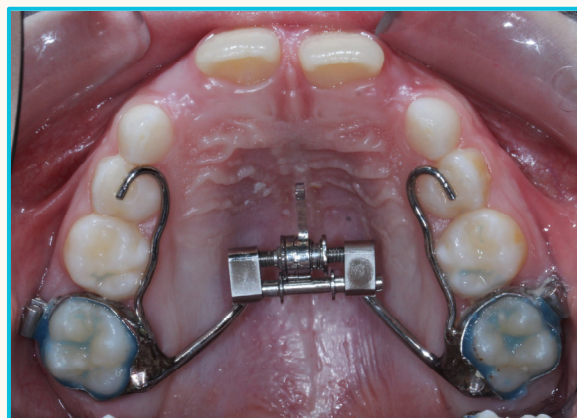- Nonextraction full comprehensive fixed orthodontic treatment

59

Occlusal view



After the cementation



15 days later, 1 turn/day

60

Frontal view

CONTACT US



Initial





15 days later

61



1 turn/day, 15 days after, the sutural separation

CONTACT US




62

Progress: Upper laterals are fully erupted



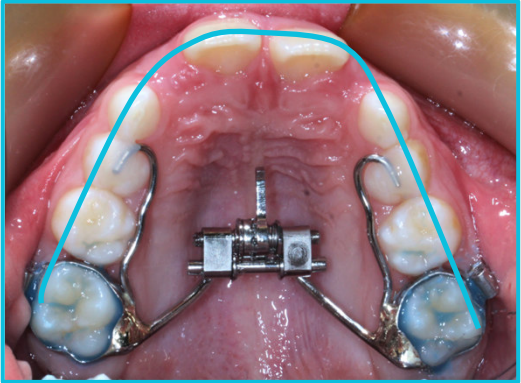

Before the expansion




1 year later

63

Progress: "V" shaped arch form become parabolic



Before the expansion





1 year later

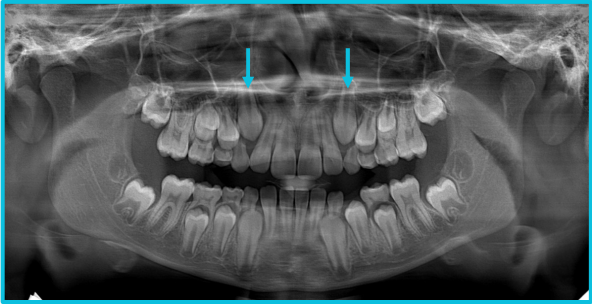
64

Progress: Upper canines started to erupt

CONTACT US



Initial



1 year later

65

Intraoral

CONTACT US




Initial




Final


66


Occlusal view






Initial







Final




67

Downward and forward growth








Initial



Final

68




Improved smile



Initial Final

69

Mandible grew and Class II profile is corrected



Initial Final

70

jco JOURNAL OF CLINICAL ORTHODONTICS

The Keles[®] Keyless Expander is featured on the front cover of JCO



MARCH 2025 ISSUE HIGHLIGHTS

3D-Printed Hybrid Keyless Expander for Maxillary Expansion and Protraction

Mr. Keles and Drs. Keles, Kayalar, Ozcan, and Akyalçin introduce a hybrid version of the Keles Keyless Expander that combines their key-free jackscrew with a customizable, metal-printed frame that can be used for the attachment of miniscrews and to support a facemask.




Dr.Keles Mr.Keles Dr.Kayalar Dr.Ozcan Dr.Akyalçin


71

Keles Keyless Expander is featured on the front cover of Journal of Clinical Orthodontics

CONTACT US




jco JOURNAL OF CLINICAL ORTHODONTICS
www.jco-online.com March 2025



72

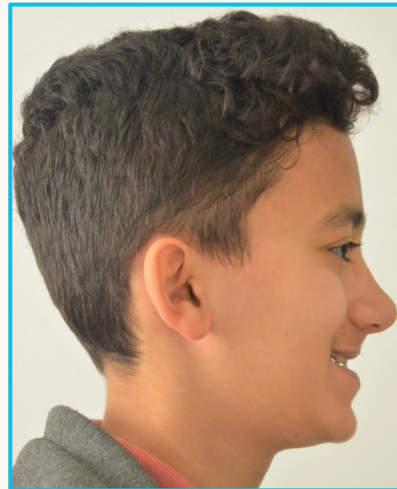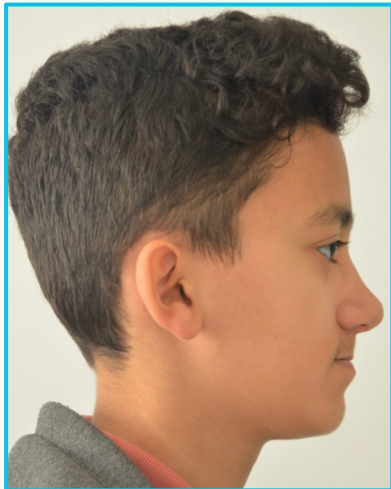Hybrid KKE/mini screws application on a 11 year 5 months old male



Class III skeletal pattern with maxillary retrusion and constriction

73



Thin retrusive upper lip and obtuse nasolabial angle



74

Initial intraoral pictures

CONTACT US



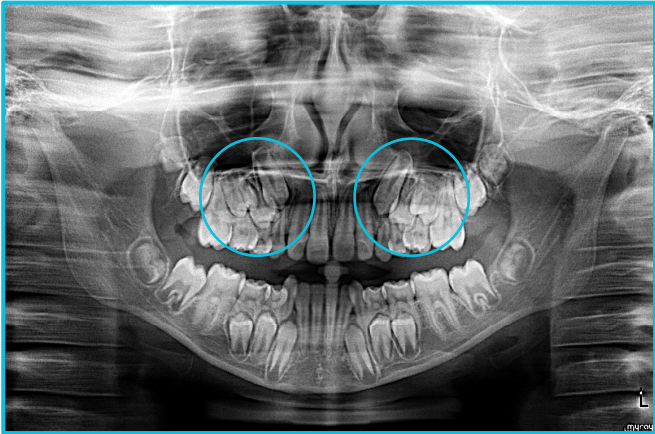

6mm crowding

4mm spacing

75


Initial panoramic radiograph


CONTACT US



76

Initial cephalometric radiograph: Retrognathic maxilla






	T0	Normal
SNA	78,3	82° ± 2
SNB	79,7	80° ± 2
ANB	-1,4	2° ± 2
WITTS	-5	-1 ± 3
N-A-Pg	3	3,9 ± 6,4
SN-GoMe	28	32° ± 7
Cond-A- (mm)	76	80
Y-axis	61	59° ± 6
U1/NA	28	22° ± 6
U1/SN	112	102° ± 5
L1/NB	18	25° ± 6
IMPA	84	90° ± 5
Upper lip/S line	-3	0
Lower lip/ S line	0	0
N'-SN-Pg'	161	161

77

Treatment plan:

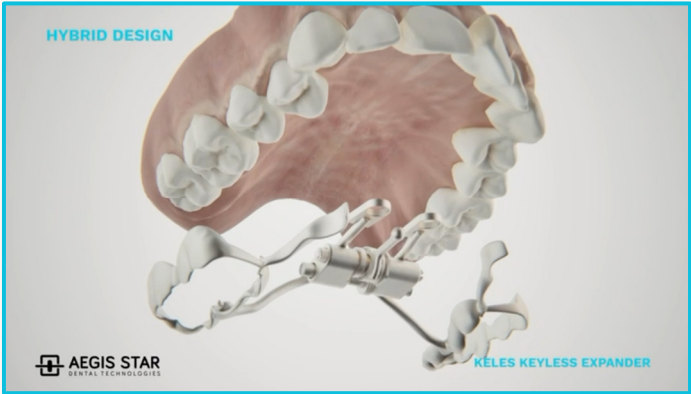



- Palatal expansion with with hybrid KKE/MARPE
- Face Mask
- Non-extraction fixed full comprehensive orthodontic treatment

78

Hybrid Design MARPE

CONTACT US



HYBRID DESIGN

AEGIS STAR DENTAL TECHNOLOGIES

KELES KEYLESS EXPANDER

79

MARPE with Fast Drive Anchor

CONTACT US



ÜRÜNLER

FastDrive 2.0x 9mm FD2009	E1 Anahıran FE 35
Vida ve Kapak Anahıran FD22	Aktarıyon kılıfı FK35
Laboratuvar Anahıdı FL33	Kaydırma Tıbbi FK36

FAST DRIVE ANCHOR

Dr. Fatih Atıcı

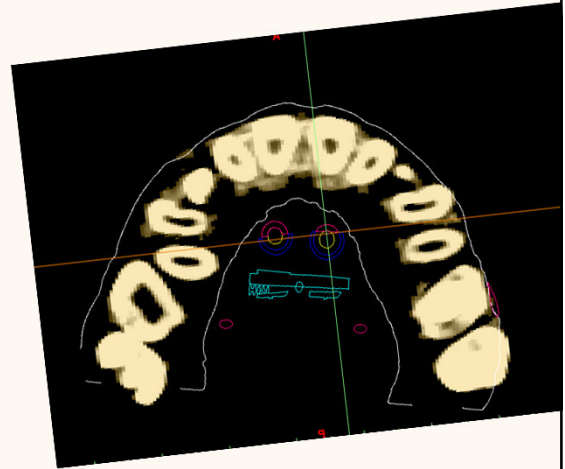
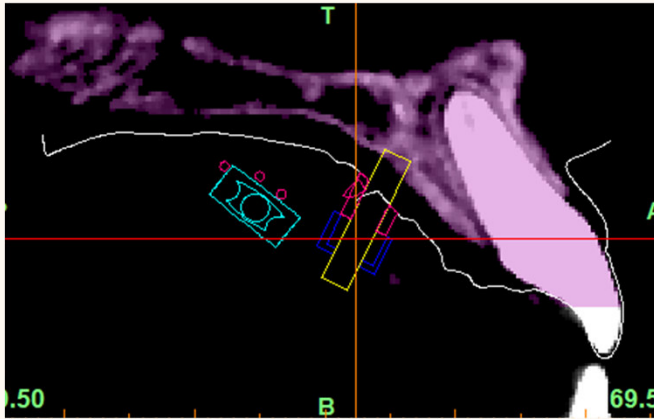
FAST DRIVE ANCHOR

1420 Sok. No:9/5 Bayrak 1 İş Merkezi
Alibucak / Zile
0232 465 11 04
0505 368 32 11
info@fastdriveanchor.com

www.fastdriveanchor.com

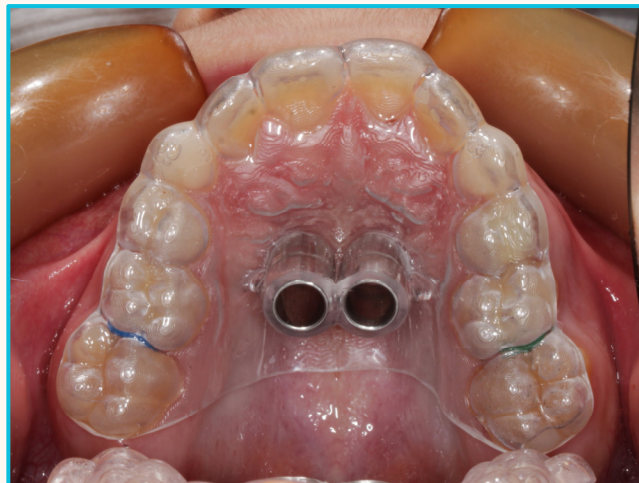80

The ideal length and diameter of the mini screw and precise orientation was determined by CBCT and intraoral scan



81




The template for precise placement of mini screws



82

Cordless low speed hand piece (30 Newton)

CONTACT US





The image shows a cordless low speed hand piece, model NSK 102000, standing upright on its base. The base is white with a digital display and control buttons. The hand piece is black and silver. A close-up view shows the tip of the hand piece, which is a high-speed burr.

83

Mini screw application with the template

CONTACT US




The image shows a close-up of a patient's mouth during a mini screw application. A clear plastic template is placed over the upper teeth. A hand piece is used to drill a hole into the bone through the template. A mini screw is then inserted into the hole. The procedure is performed by a dental professional wearing blue gloves.

84

Digital appliance design




CONTACT US




85

Metal 3D printed palatal expander framework

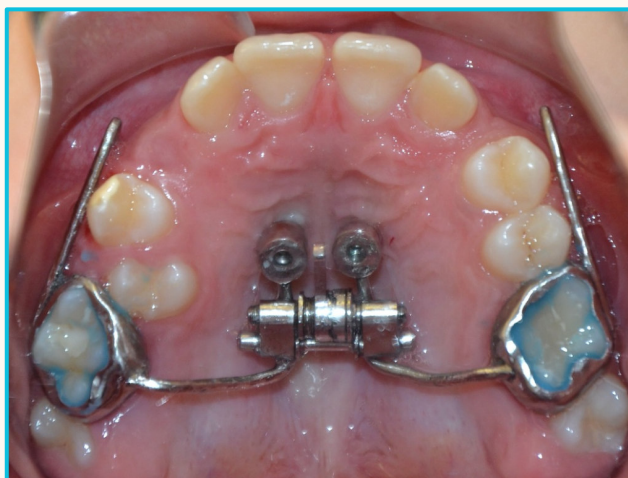

CONTACT US



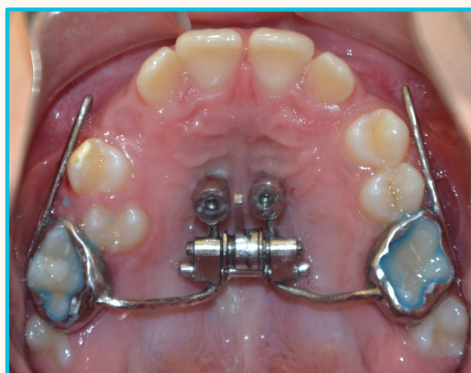86

Cementation of Hybrid KKE to the first molars and engagement with the mini-screws on the palate.

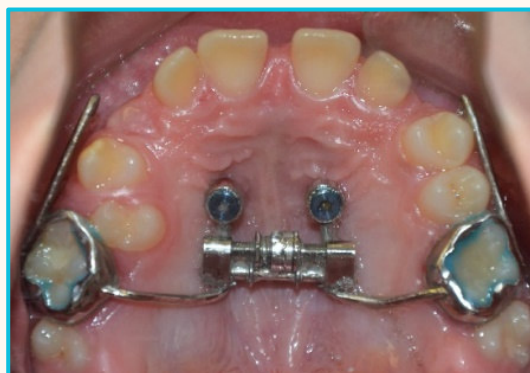

87

Effective maxillary expansion only in 2 weeks
4.6mm expansion, 1 turn/day



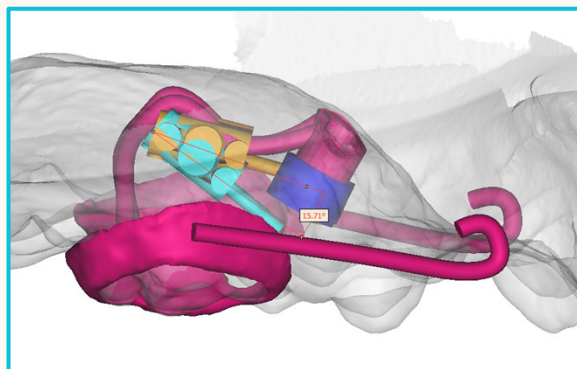
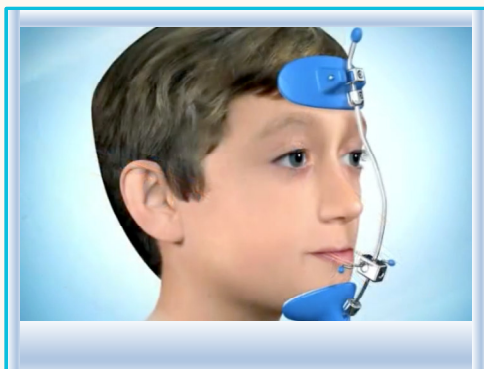
Before the expansion



14 days later

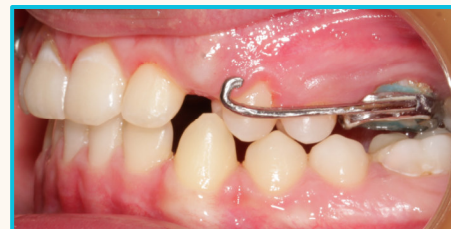
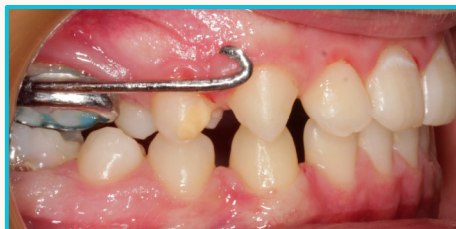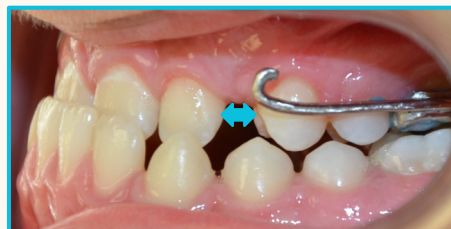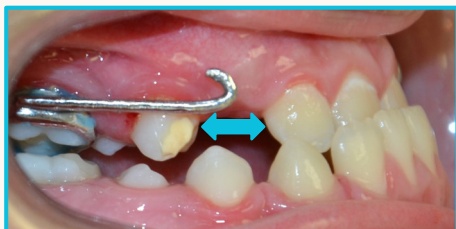88

Biomechanics of the force system of the face mask



89

Effective maxillary skeletal protraction in 1 year No dental mesial drift of the molars, Overjet went from -3mm to +4mm



90

CONTACT US



Ideal overbite and overjet and alignment of dentition




Initial



Final



91

CONTACT US





Class I molar and canine relationship is achieved

Initial






Final



92




Maxilla is expanded, crowding is eliminated and ideal parabolic arch form is achieved



Initial Final

93




Frontal:
Prominence of the upper lip and midface



Initial Final

94

Smile:
Improvement of his upper incisor display



Initial Final

95


Profile improvement:
Upper lip protrusion and ideal nasolabial angle



Initial Final


96

Initial and final cephalometric radiographs




Initial Final

CONTACT US




97

Profile improvement



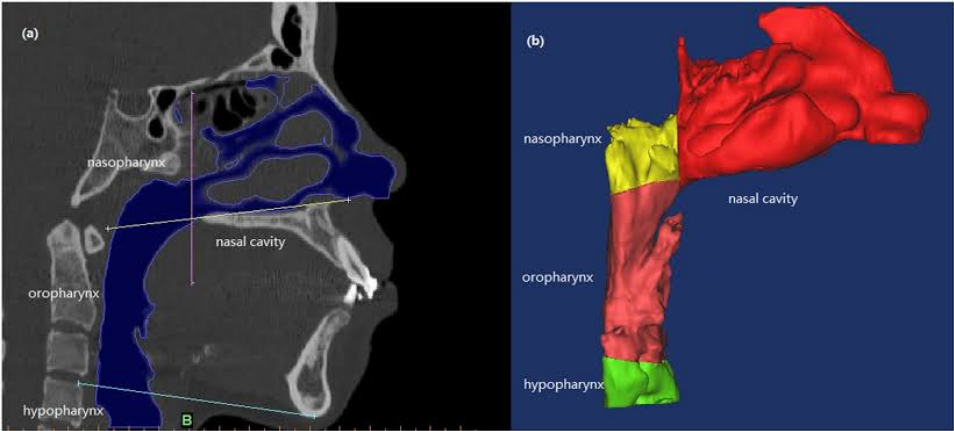

CONTACT US



98

Airway

CONTACT US




(a) nasopharynx, nasal cavity, oropharynx, hypopharynx

(b) nasopharynx, nasal cavity, oropharynx, hypopharynx

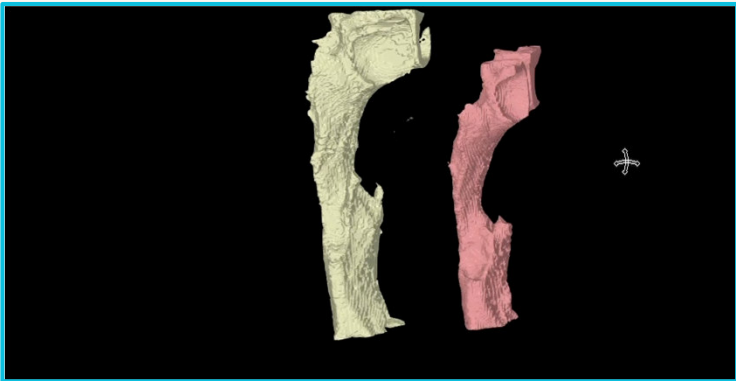
99

Significant volumetric increase in airway

CONTACT US



NemoFAB software



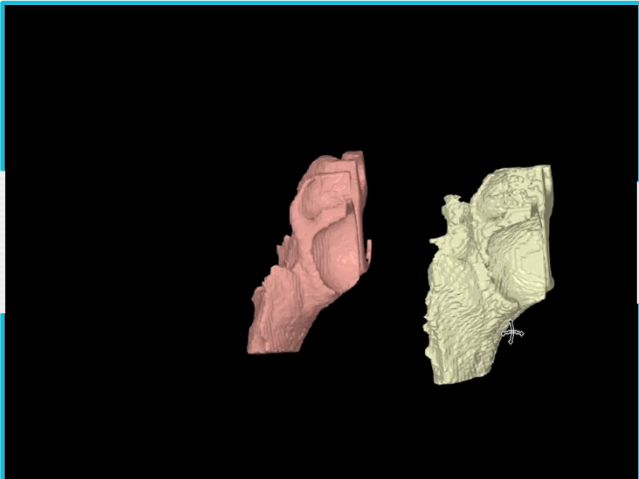
Initial (pink), Final (yellow)

100

CONTACT US

Nasopharynx (43% airway volume increase)

Volume:	6,78	C.C.
Min. Section:	65,19	mm2.
Axial Slice:	352,19	mm2.



Volume:	9,75	C.C.
Min. Section:	120,00	mm2.
Axial Slice:	393,56	mm2.

Initial (pink), Final (yellow)

101


CONTACT US

Journal of Stomatology Oral and Maxillofacial Surgery (Feb. 2026)

Comparative evaluation of Er:YAG laser assisted corticotomy vs. MARPE using the Keles Keyless Expander: A case report

Ufuk Ok^{a,*}, Eren Keles^b, Tosun Tosun^c, Fatih Atici^d, Melis Ozcan^e, Ahmet Keles^f

^a Department of Orthodontics, Faculty of Dentistry, Istanbul Okan University, Istanbul, Türkiye
^b Harvard School of Dental Medicine, Boston, MA, United States
^c Department of Oral and Maxillofacial Surgery, Istanbul Aydın University, Private Practice, Istanbul, Türkiye
^d FastDrive Anchor, 3D Orthomedikal, Izmir, Türkiye
^e Private Practice in Istanbul, Türkiye
^f Private Practice in Istanbul, Türkiye, and Part-Time Faculty, Advanced Graduate Orthodontic Program, Harvard School of Dental Medicine, Boston, MA, United States



ELSEVIER

ARTICLE INFO

Keywords:
 Laser corticotomy
 MAPRE
 SARPE
 Er:YAG Laser
 Keles Keyless expander

ABSTRACT

Objective: The aim of this comparative case report is to evaluate the skeletal, dental, and airway effects of two CAD-CAM–designed maxillary expansion protocols using the Keles Keyless Expander (KKE): a Hyrax-type expander with Er:YAG laser–assisted corticotomy(LAC), and a MARPE appliance stabilized with four palatal miniscrews. To our knowledge, this is the first report describing the use of LAC techniques in SARPE, underscoring its novelty and clinical significance.


Methods: Two female patients, both 18 years of age, were included. In the first case, a Hyrax-type expander with a 12-mm keyless screw was used, and LAC was performed with an Er:YAG laser. In the second case, a MARPE appliance with four mini-screws and an 8-mm keyless screw was applied. Pre-post-expansion cone-beam computed tomography(CBCT) scans were obtained for both patients, measurements were analyzed and compared.

Results: The KKE with corticotomy produced marked more dental effects, while the MARPE appliance showed a distinct skeletal expansion pattern. Molar inclination increased buccally by 7.8° in the laser case but decreased lingually by 1.8° in the MARPE case. The midpalatal suture opening was more parallel in the MARPE group.


Conclusion: Both expansion protocols demonstrated measurable skeletal, dental, and airway changes, yet with different patterns of response. LAC provided pronounced skeletal and dental effects, whereas the MARPE appliance achieved a more parallel midpalatal suture opening without buccal tipping of molars. These differences highlight the importance of appliance selection and adjunctive techniques in treatment planning. Larger prospective studies are needed to confirm long-term stability and clinical applicability.

102

18 years old female, narrow upper jaw and convex profile, forward head posture and mouth breathing



CONTACT US



103

Anterior crowding and posterior constriction

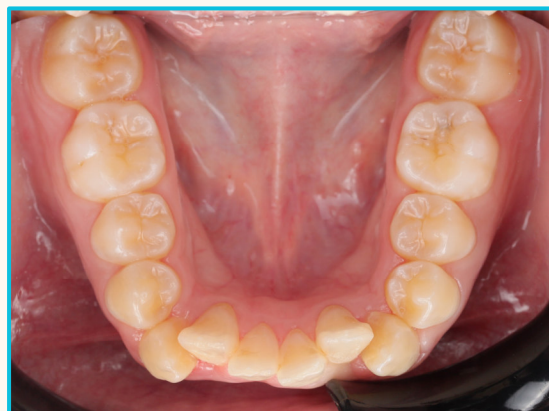
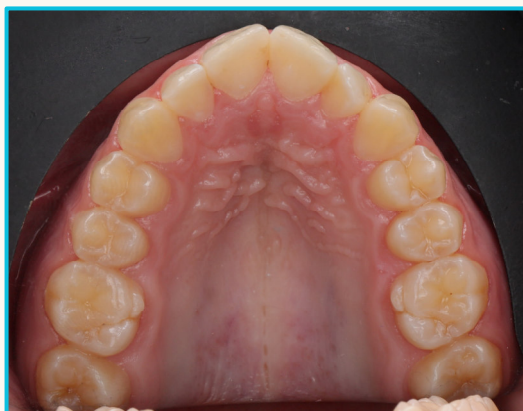

CONTACT US




104

V shaped upper arch and posterior constriction



105

Treatment plan:





- Mini-screw assisted slow palatal expansion (MASPE) with 4 mini-screw anchored KKE
- Non-extraction fixed full comprehensive orthodontic treatment

Dr. Ufuk Ok

106

One Appointment Anchorage System No need for a template









Code	Description	L	A
8GL14	14/8 GUIDE LOCK Palatinal Screw	14	8
9GL14	14/9 GUIDE LOCK Palatinal Screw	14	9
10GL14	14/10 GUIDE LOCK Palatinal Screw	14	10
8GL16	16/8 GUIDE LOCK Palatinal Screw	16	8
10GL16	16/10 GUIDE LOCK Palatinal Screw	16	10
10GL18	18/0 GUIDE LOCK Palatinal Screw	18	10
10GL20	20/10 GUIDE LOCK Palatinal Screw	20	10

Code	Description	L
GL4L	GUIDE LOCK Connector	4
GL3L	GUIDE LOCK Ring	3









107

One Appointment Anchorage System No need for a template

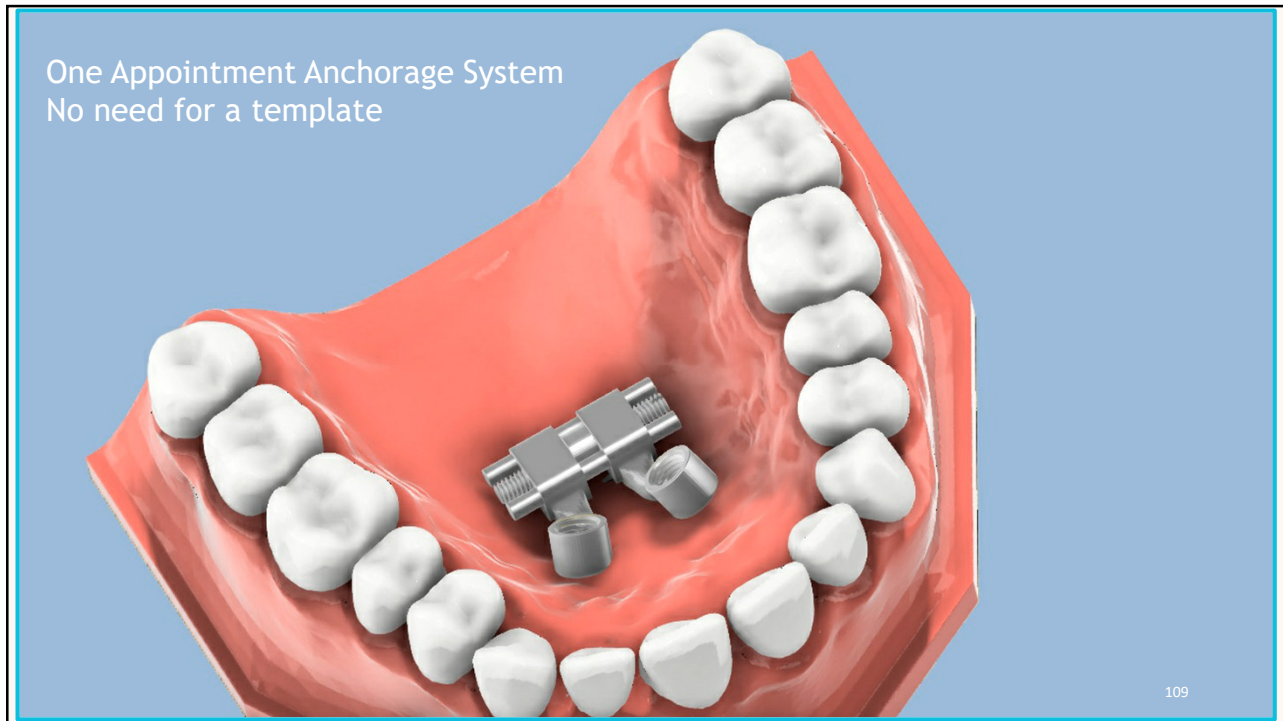




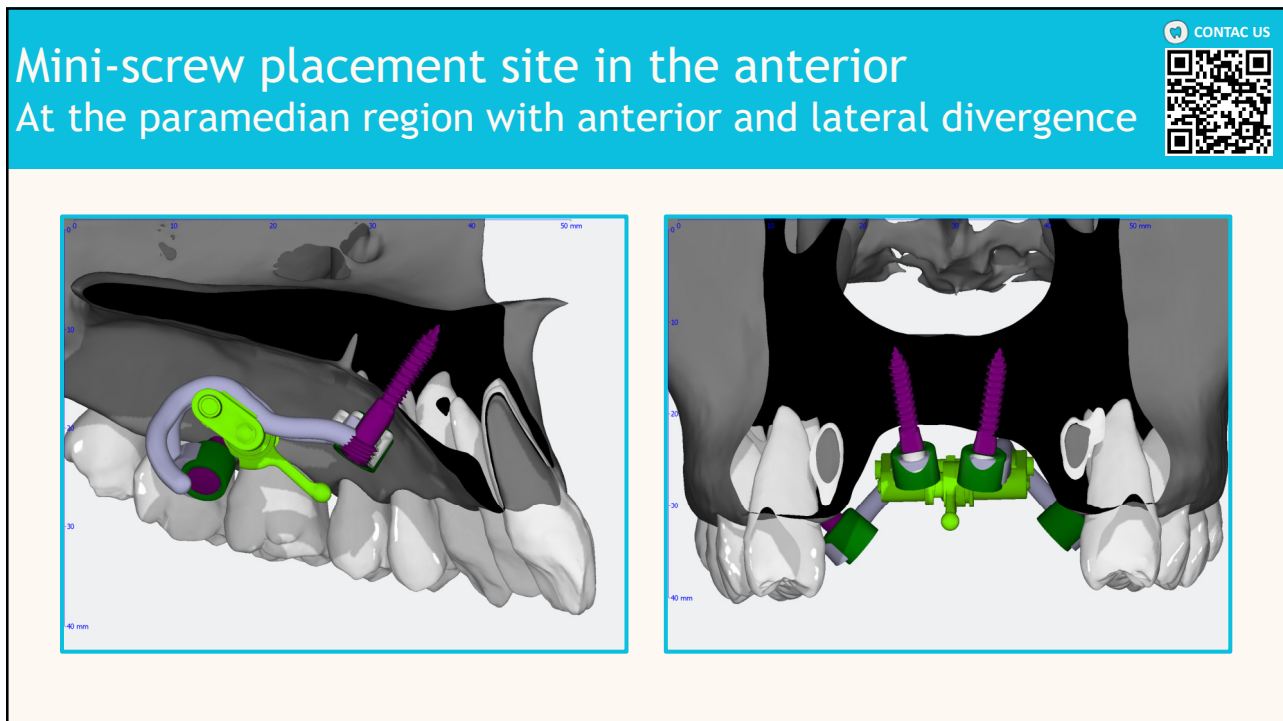
One Screw For All Anchor Applications
One Appointment Anchorage System

		
GUIDE LOCK Palatinal Screw <small>(CO 3822 3 T-SAN-4V) (Titanium)</small>	Connector <small>A02 316 L Stainless Steel</small>	
		
TB Screw Driver <small>Hardened Medical Grade Surgical Instrument Steel</small>	Drill Guide <small>(CO 3822 3 T-SAN-4V) (Titanium)</small>	Drill Guide Driver <small>Hardened Medical Grade Surgical Instrument Steel</small>
		
Connector Drill with stop <small>Hardened Medical Grade Surgical Instrument Steel</small>	Screw Head Detail	Assembled with connector

108



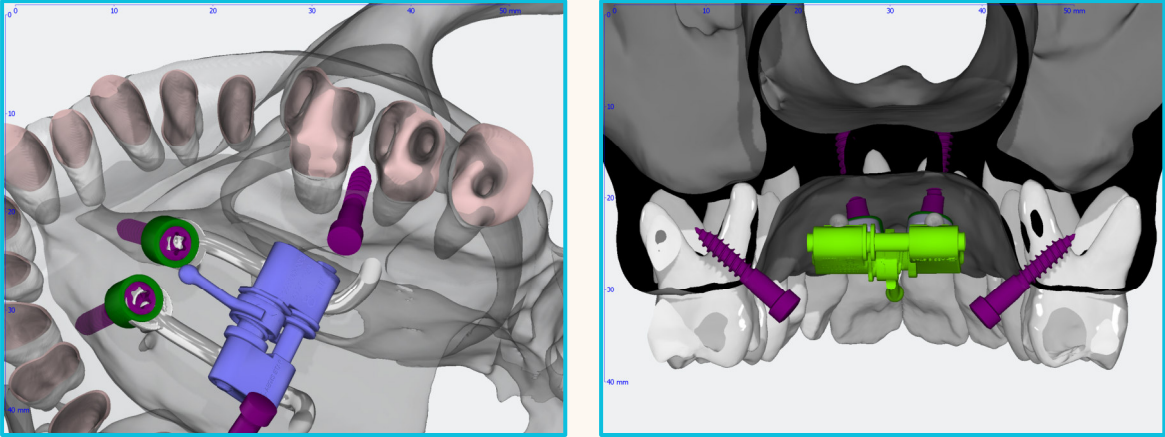
109




110

Mini-screw placement site in the posterior

Between the palatal roots of 1st and 2nd molars




CONTACT US




111

Mini-screw placement sites in the anterior and posterior

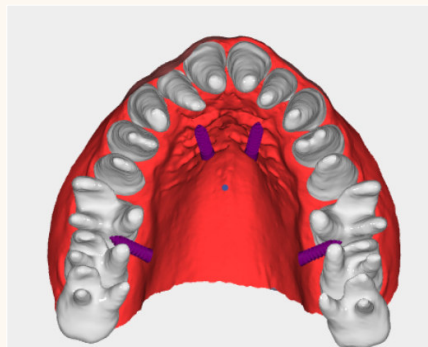
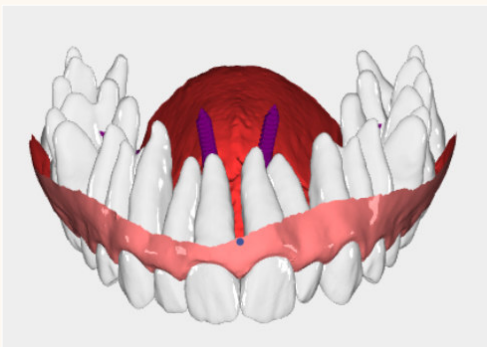



CONTACT US



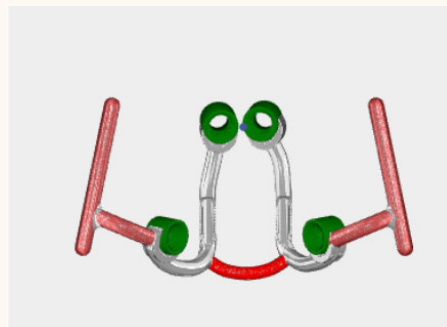
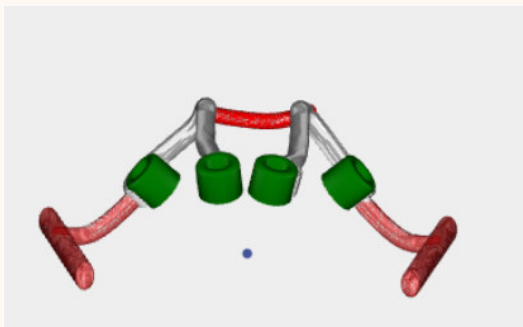

112

Proper orientation of the 4 mini-screws integration of intraoral scan and CBCT

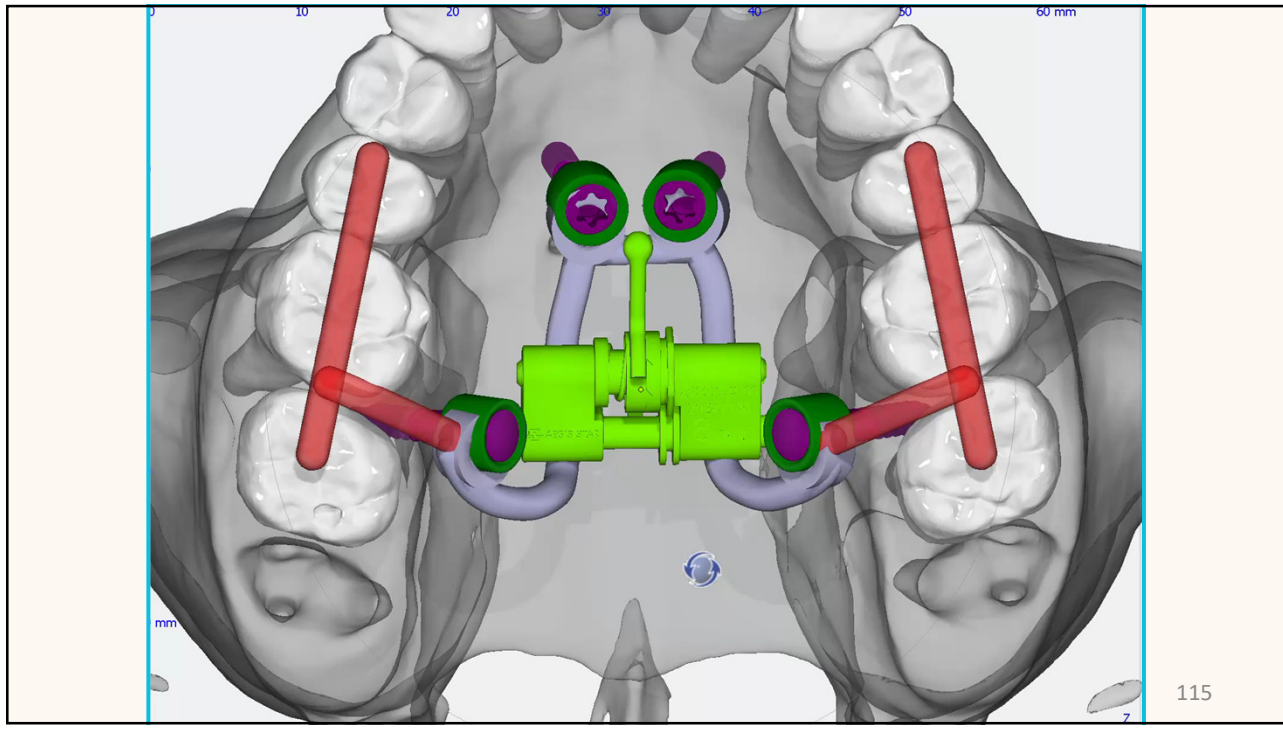


113

Digital appliance design planning and construction of the framework

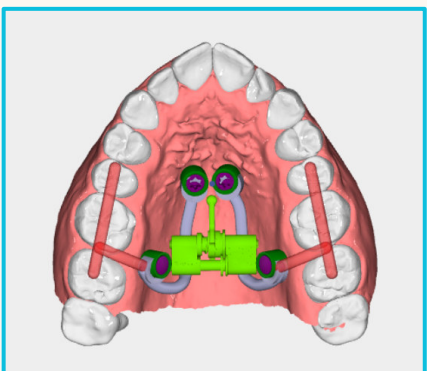



114

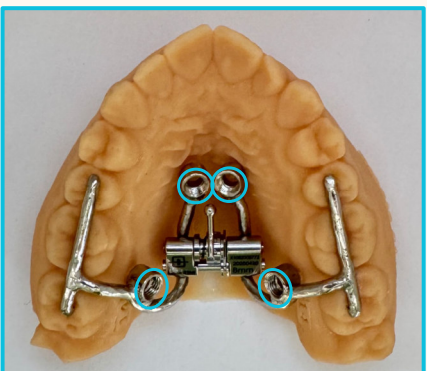


115

Customization with the 3D metal printed framework



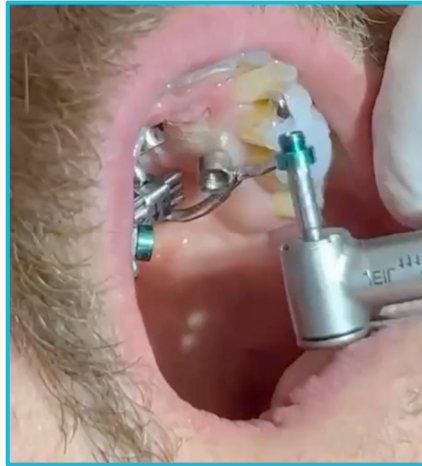Digital framework design



Threaded rings

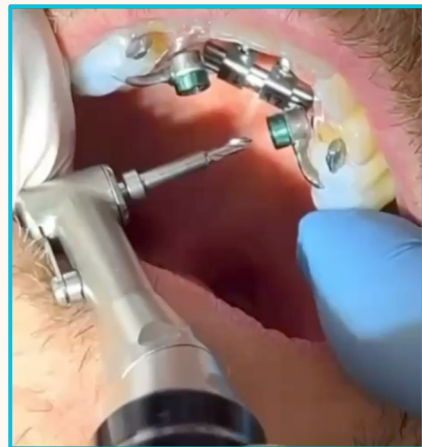
116

Demonstration of the placement of the mini-screw First insertion of the pilot drill connector



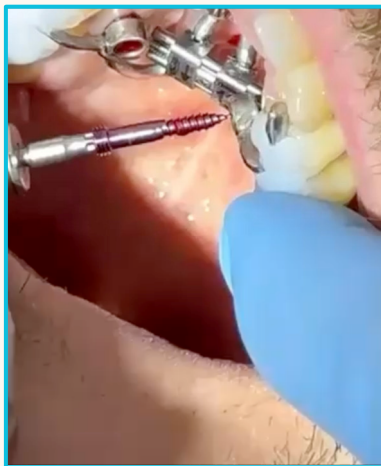117

Insertion the pilot drill (3mms)



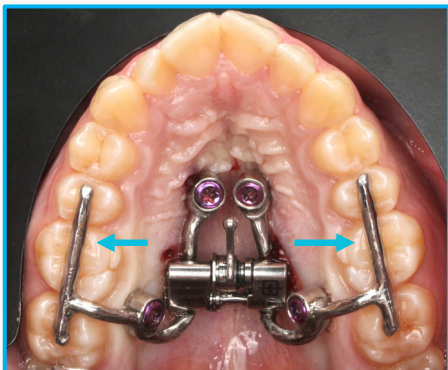
118

Insertion of the mini-screw

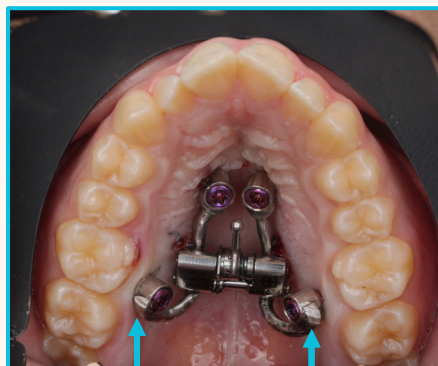

119

Application of KKE with mini-screws



Occlusal stands for precise placement



Cut the occlusal stands from the rings with the carbide bur

120

Full bone-born skeletal expansion (MASPE) 1 turn every other day.



Initial





50 days later


40 days later

121

Effective palatal expansion



Initial





50 days later


122

Midline diastema

CONTACT US



Initial

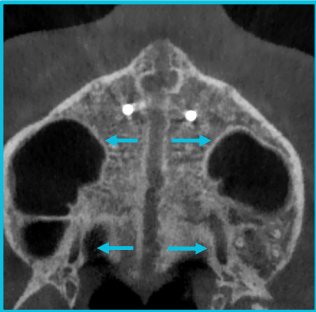



50 days later

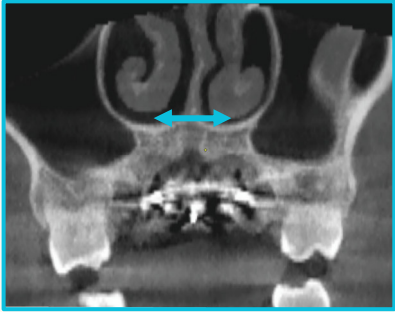
123

Parallel sutural opening

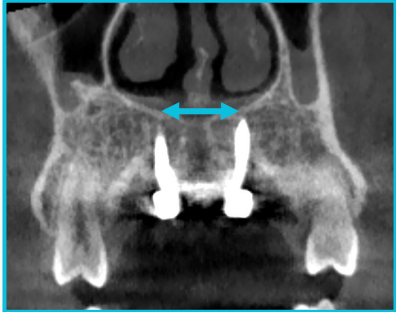
CONTACT US



Parallel opening



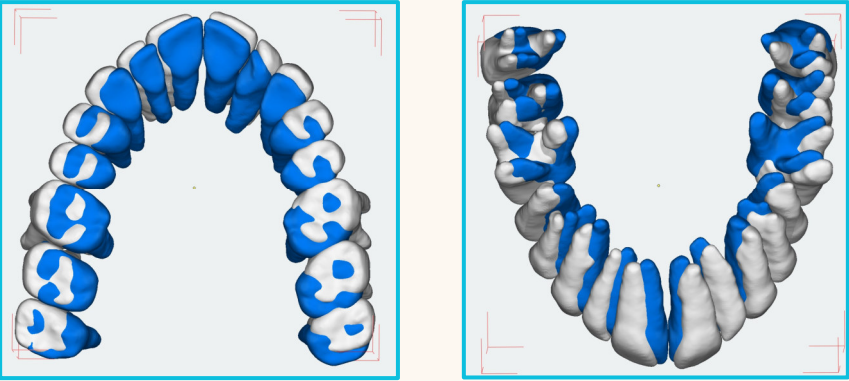
2nd molar region




1st premolar region

124

CBCT imaging overlay before/after the expansion Initial (blue), after the expansion with KKE (white)

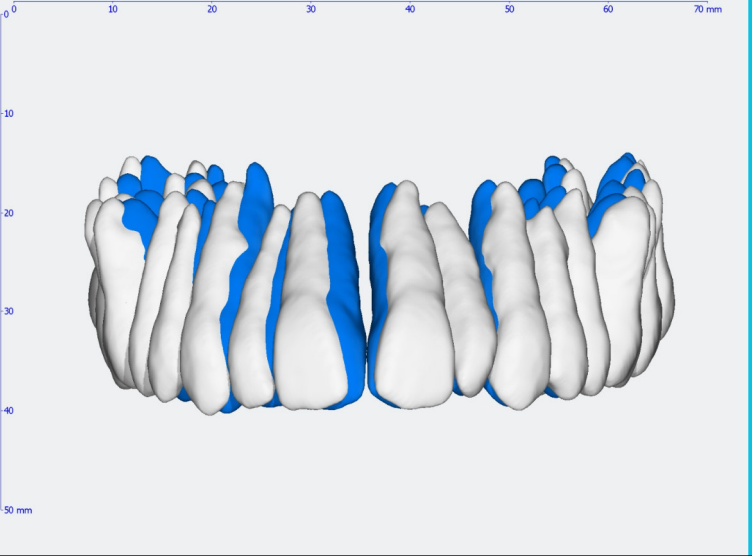


CONTACT US




125

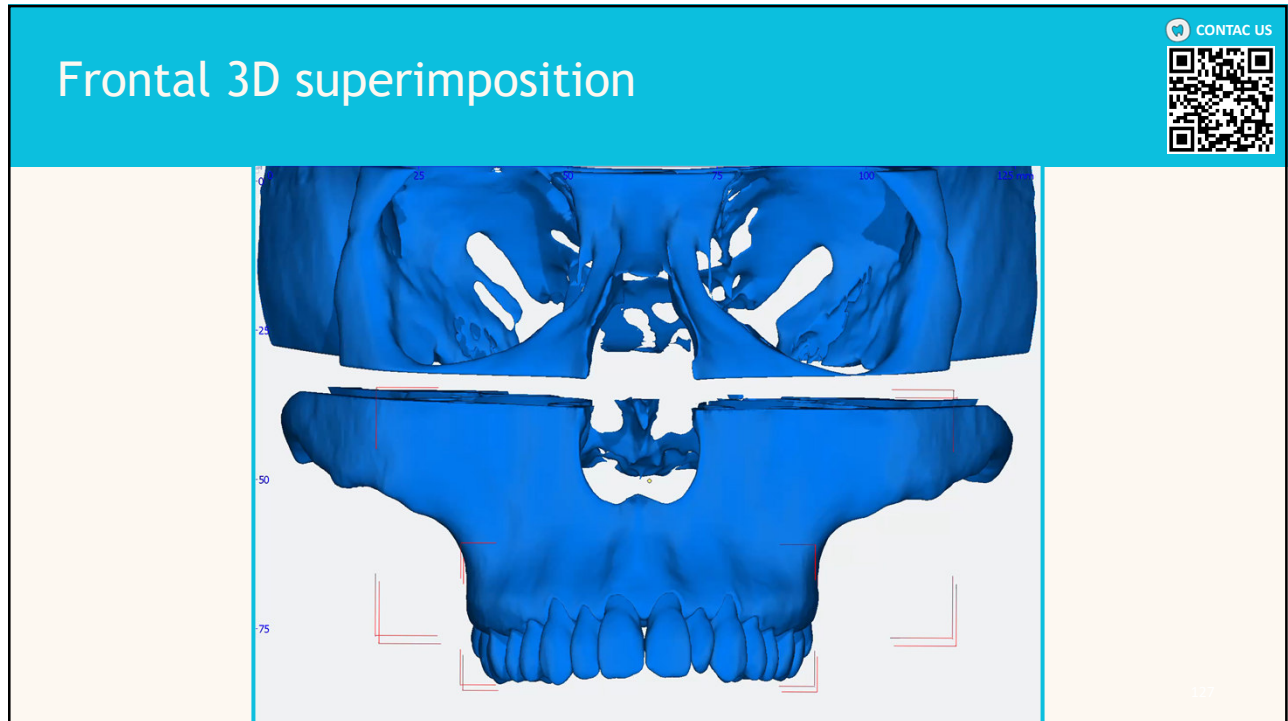
No extrusion of dentition, pure parallel skeletal transverse expansion



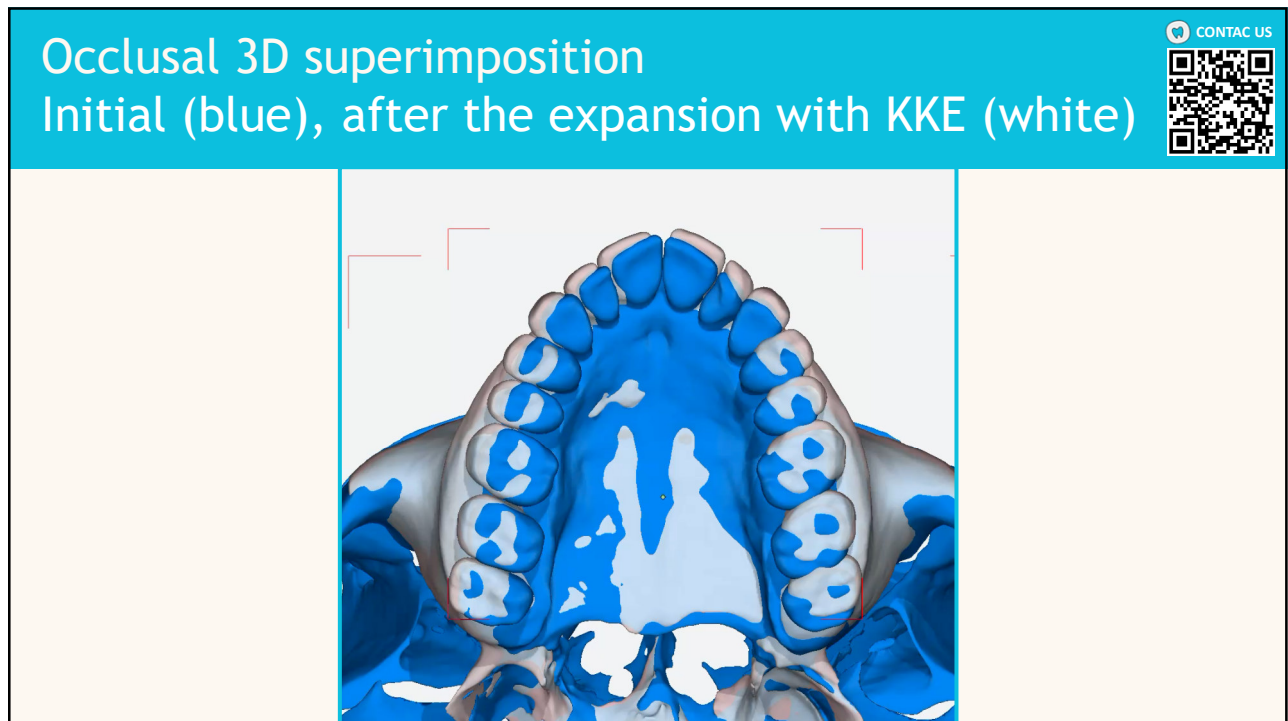
CONTACT US



126

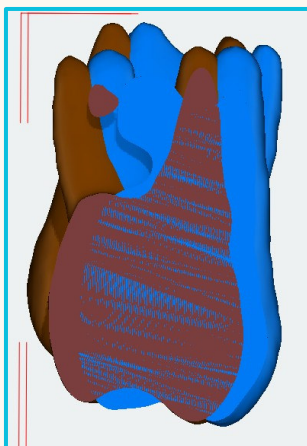


127

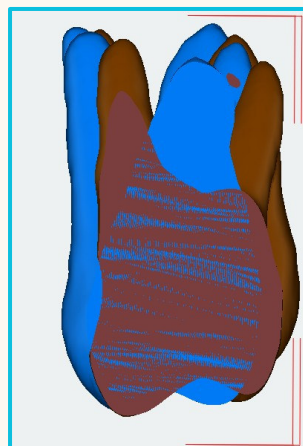


128

Parallel sutural opening, skeletal expansion. No buccal tipping of molars



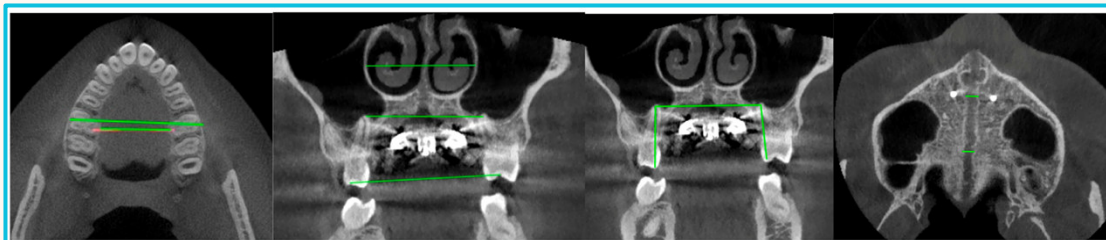
Right side



Left side

129

CBCT measurements:



- Maxillary width
- Nasal width
- Inter-molar width
- Molar inclination
- Mid-palatal suture opening distance (Anterior/Posterior)

130

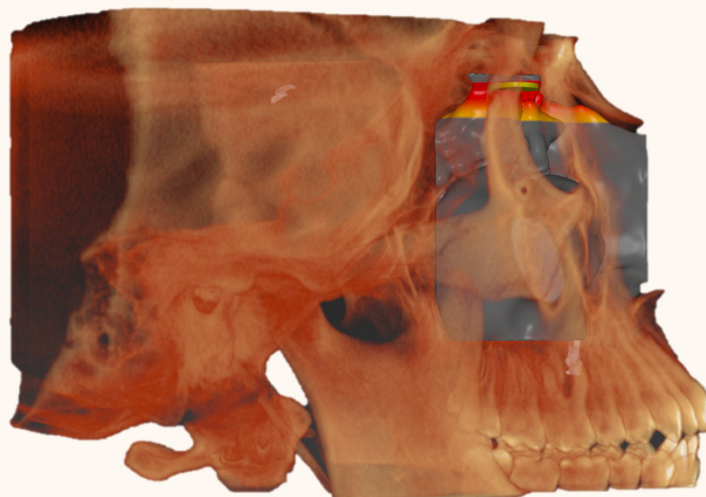
3.35mm pure skeletal maxillary expansion is achieved



		T0	T1	ΔT (T1-T0)
Linear Measurement (mm)	External maxilla	54.55	57.9	3.35
	Internal maxilla	27.7	30.6	2.9
	Palatinal roots	31.05	34.9	3.85
	Santral fossa	43.75	45.4	1.65
	Nasal Floor	28.6	31.6	3
Midpalatal Suture Opening Pattern		Posterior	Anterior	0.11
		3.75	3.86	
Angular measurement	Right First Molars	96.4	92.6	-1.8
	Left First Molars	97.4	94.8	-2.6



131

CBCT evaluation of airway: Initial/6 months after the expansion



132

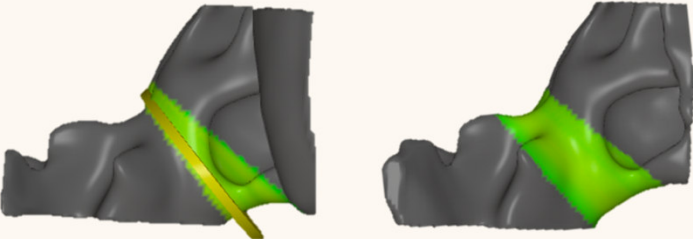

Nasal volume increase: 3,6cm³



Nasal cavity		
T0	T1	T1-T0
24,7	28,3	3,6

133

Nasopharynx volume increase: 0,9cm³



Nasopharynx		
T0	T1	T1-T0
6.8	7.7	0.9

134

Science behind KKE:

- 3 independent PhD. thesis research projects
- 5 case reports
- 1 clinical trail




135

Published articles:




136

Dr. Luke Shapiro's patient
Wall Street Orthodontics, New York City, April 2026




CONTACT US



137

Discovery is seeing what everyone else has seen
and thinking what no one else has thought.
Albert von Szent-Györgyi




**THE KELES
KEYLESS
EXPANDER**

INNOVATION IN ORTHODONTICS



Successfully treated
3000+
patients

CONTACT US



138

Thank You



Ahmet_Keles@hsdm.harvard.edu

www.aegis-star.com

139



<https://champions.learner.plus/sec/>

MARPE appliances

What inspired you to reflect?

Pick the context and a clinically relevant concept or phrase that inspired you to reflect.

Reflective Learning Moment

MARPE appliances

Step 1 of 4

Next

140